

ISSN 1824-0852

Trimestrale - Poste Italiane S.p.A. - Spedizione in abbonamento postale D.L. 353/2003 (convertito in legge 27/02/2004, n. 46, art. 1, comma 1, DCB Roma)
In caso di mancato recapito inviare al C.P.R. Roma, Roma, Roma Stamp per restituzione al mittente previo pagamento resi
Carliana I.P.

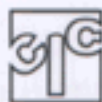ANNALI DI STOMATOLOGIA

ORGANO UFFICIALE
DEL



A Journal of Odontostomatologic Sciences

Vol. LIV - No. 1 - January/March 2005 - Quarterly



CIC Edizioni Internazionali

Glosso-postural syndrome

Fabio Scoppa

Scientific and Educational Coordinator, Master's Degree Course in Posturology
 Director: Prof. Giuseppe Amabile
 1st Faculty of Medicine and Surgery, University "La Sapienza", Rome, Italy

Correspondence to: Prof. Fabio Scoppa
 Via Guido Cavalcanti, 2 - 00152 Roma - Italy
 E-mail: posturologia@uniroma1.it
 www.posturologia.biz

Submitted for publication: 31/08/2004

Accepted for publication: 16/11/2004

Summary

Glosso-postural syndrome

Atypical deglutition is correlated not only with posture and orocraniocervical morphology, but also with the subject's general posture.

The tongue is capable of perturbing postural balance due both to its connections with the key anatomical structures, and to other neurophysiological reasons.

The hyo-glossus apparatus, owing to its links with the maxillaries, the skull, the cervicals, the scapula, the pharynx and the larynx, is the true "trait d'union" between the oral and postural functions of the body.

Due to the prevalently transverse arrangement of its fibres, the tongue may be considered a diaphragm linking the body's anterior and posterior muscular chains. In this report, we present a new nosographical entity, glosso-postural syndrome, which is characterized by postural imbalance and atypical deglutition.

The most important traits of type I and type II glosso-postural syndrome are described.

Key words: atypical deglutition, glosso-postural syndrome, postural imbalance.

Sommario

La sindrome glosso-posturale

La deglutizione atipica è correlata non solo con la postura e la morfologia oro-cranio-cervicale, ma anche con la postura generale del soggetto.

La lingua è in grado di perturbare l'equilibrio posturale grazie alle sue connessioni con strutture anatomiche di capitale importanza, oltre che per ragioni di ordine neurofisiologico.

L'apparato io-glosso, in virtù dei suoi legami con i mascellari, il cranio, le cervicali, le scapole, la faringe e la laringe rappresenta il vero "trait d'union" tra funzioni orali e funzioni posturali corporee.

Per la disposizione prevalentemente trasversale delle sue fibre, la lingua può essere considerata un diaframma che mette in comunicazione le catene muscolari anteriori e posteriori del corpo.

Nel presente lavoro viene presentata una nuova entità nosografica, la sindrome glosso-posturale, caratterizzata da squilibrio posturale e deglutizione atipica.

Vengono descritti i caratteri salienti delle due varietà di sindrome glosso-posturale, il tipo I e il tipo II.

Parole chiave: deglutizione atipica, sindrome glosso-posturale, squilibrio posturale.

Introduction

In recent years, specialists from various disciplines have studied the problem of atypical deglutition: a wide range of literature exists, also in Italian, describing the negative effects of deglutition disorders at different levels – orthognathodontic, logopaedic, otorhinolaryngoiatric, paediatric (Balercia, 1993; Caprioglio, 1993 a, b; Cozza, 1995; Capurso, 1996; Garliner, 1996; Walther, 1996; Ferrante, 1997; Funt, 1999; Cozza, 2002; Stefanelli, 2003; Ferrante, 2004).

In general, the morphogenetic role of the tongue, capable of modelling the arches and affecting the development of the maxillaries, regards mainly the developmental phase of life, after which it is not rare for the tongue to fulfil a balancing and a compensatory function, acting as a sort of natural bite. Especially in adulthood, the tongue is capable of compensating for missing teeth, malocclusions, or lack of orthogonality between the occlusal plane and the vertebral sagittal plane.

In this regard, just as atypical deglutition can be considered a cause of malocclusion, so, in malocclusion, the tongue can serve an occlusion stabilizing function and behave in an atypical way.

Such considerations bring us back to the relationship between structure and function, which, from our point of view, cannot be regarded as a simple linear relationship of cause and effect, but rather as a complex, circular and systemic type relationship (Fig. 1).

The age-old debate over whether it is the orofacial musculature that affects the teeth or rather the teeth that affect muscular function can be overcome by performing a differential diagnosis involving muscular tests, by studying the deglutition pattern, and by examining the occlusion.

It is a topic that continues to be the focus of considerable attention among professionals (Lang, 2004; Peng, 2004; Solomon, 2004).

Many (Balercia, 1993; Caprioglio, 1993 a, b; Bricot, 1996; Ferrante, 1997; Ranaudo, 1997; Cipollari, 2003;

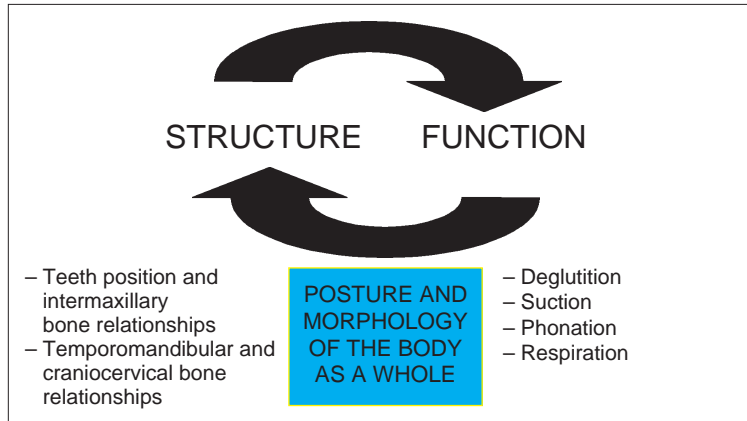


Figure 1 - The tongue constitutes an excellent example of the intimate and reciprocal interrelation between structure and function.

Guaglio, 2003; Lentini, 2003; Spinicci, 2003; Stefanelli, 2003; Ferrante, 2004; Zavarella, 2004) also stress the relationship between lingual dysfunction and postural problems, these authors describing differently, however, and in some cases perhaps inaccurately the terms of this relationship or the types of postural imbalance involved. Consequently, we feel that there is a need to define a clear nosographical entity in order to describe the types of postural imbalance found in subjects with atypical deglutition. We propose such a nosographical entity, which we call glosso-postural syndrome.

General considerations on the relationship between posture and lingual functions

Every individual develops a model of deglutition – an engram that is based on the phylogenetic, ontogenetic and environmental information received. The deglutition pattern can both stimulate and damage stomatognathic function. In deglutition disorders, the tip of the tongue, rather than curving upwards in the direction of the retroincisor spot, may push against the top or bottom teeth, or interpose itself between them.

This lower and anteriorized position of the tongue, due to the anomalous thrusts during deglutition, which may be repeated up to two thousand times a day, can cause alterations in the spatial arrangement of the teeth and maxillary bone, and also have negative repercussions on the general posture of the individual.

Just as occlusion and stomatognathic balance can be regarded as linked to general postural balance, so lingual functions can be considered part of the global bodily equilibrium.

In our opinion, the tongue constitutes an excellent example of the intimate and reciprocal interrelation between structure and function. The posture and the morphology of the body as a whole are the result of this reciprocal relationship (Fig. 1).

First of all – and here I take into consideration only the orocraniocervical region –, the lingual functions and the intermaxillary, temporomandibular and craniocervical morphopostural parameters constitute the variables of a system that is subjected to reciprocal regulation.

Thanks to its peculiar innervation and motility, the tongue can occupy the space that is put at its disposal, and can adapt to restricted spaces, and increase in its longitudi-

nal diameter compensating for reduction of its transverse diameter; it is also capable of filling spaces left by missing teeth, and of twisting about its major axis, adapting to developmental asymmetries of the palate.

The tongue is thus correlated with the position of the teeth, with the intermaxillary relations, with the effectiveness, or inadequacy, of the labial seal (nasal or oral respiration), and with the equilibrium of the occipito-atlantoid joint.

In deglutition disorders, the occipito-atlantoid relationship, influenced by the muscular pull of the tongue, is altered, giving rise to adaptations and compensations involving the whole locomotor apparatus.

Atypical deglutition is therefore connected not only with orocraniocervical posture and morphology, but also with the general posture of the subject.

The tongue is capable of perturbing postural balance due to its connections with the key anatomical structures:

- anteriorly: through the hyoid bone, it is part of the muscular-aponeurotic system that involves the entire locomotor apparatus;
- posteriorly: through the glossopharyngeal muscles and the middle constrictor of the pharynx in particular, it affects the equilibrium of the cervical rachis;
- at cranial level, through the action of the styloglossus and stylohyoid muscles;
- at mandibular level, both through the direct thrust on the dental elements and through the action of the genioglossus, the geniohyoid and the mylohyoid.

At cranial level, a function of the tongue that is fundamental for craniosacral mobility is lost in atypical deglutition.

During normal deglutition, the tongue, through contraction of the styloglossus muscle, exerts a traction force on the base of the skull.

By inserting on the root of the tongue and on the styloid process of the temporal bone, the styloglossus, during correct deglutition, pulls the base of the tongue upwards and backwards, simultaneously compressing the tongue against the palate and exerting a direct action on the cranial base and on the maxillaries.

During correct deglutition the traction of the styloglossus muscle on the posterior cranial ball favours normal cranial mobility and harmonizes the craniosacral relations through the dural route.

At the same time, the tip of the tongue presses against the anterior palate transmitting a force through the vomer

to the sphenoidal rostrum; this faint pressure allows a slight mobilization of the sphenoid which is crucial to the craniosacral system (Perroneaud-Ferré, 1989; Lignon, 1989; Upledger, 1996; Sutherland, 2002 a, b).

The pressure of the tongue on the retroincisor spot during physiological deglutition also has considerable neurophysiological significance, as documented by recent research. Particularly important is the research that has demonstrated the presence of as many as five types of exteroceptor in the single square centimetre of the palate corresponding to the retroincisor spot (Halata, 1999).

Furthermore, other researchers showed that the elevation of the tongue, compared with deglutition, activates a greater total volume of cerebral cortex, with significantly increased activation in the cingulate gyrus, supplementary motor area, precentral and postcentral gyrus, premotor cortex, putamen and thalamus (Martin, 2004).

These data give us an idea of just how important, at neurophysiological level, the elevation movement of the tongue is in the stimulation of the retroincisor spot, and of the extent to which the information originating from this zone may affect the central regulation mechanisms of posture.

On the other hand, if it is true that deglutition is capable of affecting posture, the opposite is also true. Correct postural alignment is important in normal processes of deglutition and ingestion of food: this aspect is particularly striking in the field of neurological pathologies (Redstone, 2004).

In short, we do not feel that, to date, adequate consideration has been given to the fundamental nature, in central regulation mechanisms of posture, of the information originating from this area.

On a functional level, due to the prevalently transverse arrangement of its fibres, the tongue may be considered a diaphragm linking the body's anterior and posterior muscular chains. Through the lingual septum and the hyoglossus membrane, the tongue forms intimate relationships, in the fascial plane, with the hyoid bone; the correlation between tongue and general posture is thus found at aponeurotic as well as at muscular level.

Still on a functional level, the whole muscular-aponeurotic system that links the tongue with the internal organism, might be termed the lingual chain (Clauzade, 1989, 1992, 1998).

The lingual chain

By lingual chain we mean the ensemble of muscles and aponeurosis topographically positioned in the anteromedial region of the body, following a longitudinal sequence (Denys-Struyf, 1982; Fig. 2).

On both motor and postural levels, the lingual chain is a functional unit; anatomically, it is made up of a very rich network of muscles and aponeurosis, which explains its importance in posture.

The hyo-glossus apparatus, owing to its links with the anatomical structures at cranial, caudal, ventral, and dorsal levels, is the true "trait d'union" between the oral and postural functions of the body.

In view of its relations with the maxillaries, the skull, the cervicals, the scapula, the pharynx and the larynx, it is easy to appreciate the strategic influence of the hyoglossus apparatus on the postural system.

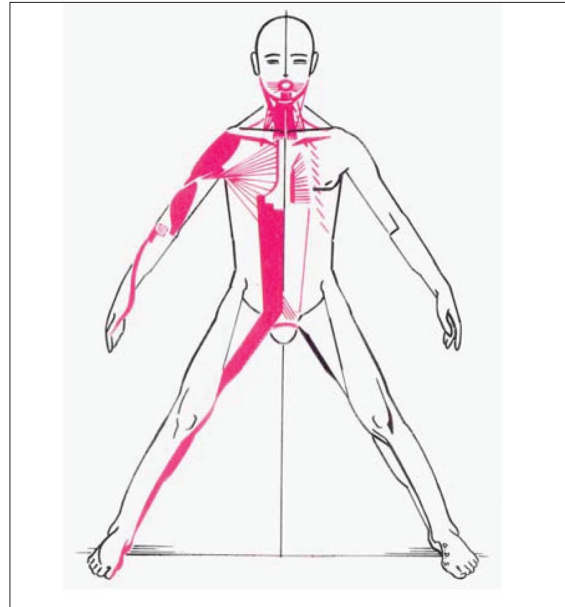


Figure 2 - Anteromedial muscular chain (Denis-Struyf, 1982).

Normally, a lingual dysfunction causes a fulcrum of rotation on the hyoid bone leading to rotation and imbalance of the scapular girdle, followed by a succession of compensations on the whole locomotor apparatus.

The tongue and the hyoid bone, thanks to the superficial cervical aponeurosis, middle cervical aponeurosis and deep cervical aponeurosis, are able to influence profoundly the morphopostural organization of the body as a whole (Fig. 3).

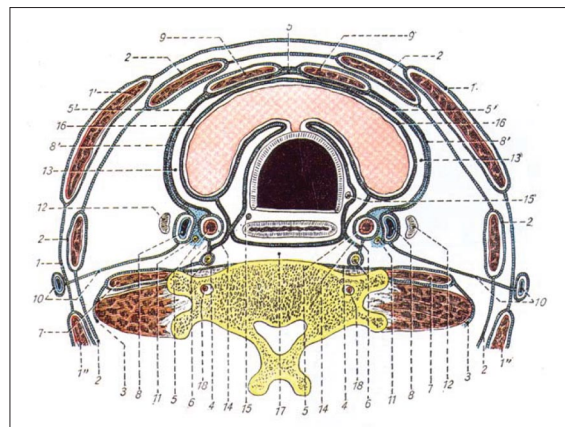


Figure 3 - The visceral cavity in the inferior zone of the neck, as described by Testut (1971). 1. superficial cervical fascia; 1' sternocleidomastoid m.; 1'' trapezius m.; 2. middle cervical fascia; 3. deep cervical fascia; 4. prevertebral fascia; 5. common carotid a.; 5' arterial vascular fascia; 6. sagittal segment wrapping the sympathetic; 7. anterior scalenus wrapped in its fascia; 8. internal jugular v.; 8' venous vascular fascia; 9. sternothyroideus m. wrapped in its fascia; 10. transverse cervical venous fascia, depending on the external jugular v.; 11. vagus n. included in the attachment of the vascular laminae; 12. lymph nodes; 13. visceral cavity; 14. vasa fascia of the cephalic intestine; 15. tracheo-esophageal sheath where the recurrent n. resides; 16. thyroid gland sheath or capsule; 17. retrovisceral space; 18. vertebral a.

Theoretically – and this is because of proprioceptive control reasons as well as the aponeurotic concatenation mentioned earlier – there is no part of the body that does not respond in some way to modification of the hyo-glossus apparatus relations.

On a proprioceptive and postural level, the hyoid bone has been likened to a gyroscope in a driving system (Clauzade, 1992; Garliner, 1996).

Not having bone contacts and being suspended rather like a “hammock”, it can act as a gyroscope supplying the brain, through the neuromuscular spindles, with information regarding the bodily equilibrium. The position of the hyoid bone, which should be strictly horizontal, reflects the tension of the muscles, aponeurosis and ligaments to which it is linked. Anomalous dislocation or reduction of the mobility of the hyoid bone, active or passive, are pathognomonic of tension in the individual's fascial and visceral structure.

Type 1 glosso-postural syndrome

This is the most frequent postural imbalance (85% or more) in subjects with atypical deglutition (Fig. 4).

The fundamental characteristic of this imbalance is anteriorization of the scapular plane with respect to the gluteal plane (Figs 4, 5, 6). It may be (but is not necessarily) associated with a class II occlusion: indeed, this anteriorization can also be present in subjects with a class III functional occlusion (Fig. 5). On a neuromuscular level, this anterior projection of the scapular plane may be considered the result of predominance of the anteromedial lingual chain over the other kinetic chains. Apart from the anterior scapula, which is a major postural problem in itself, type 1 glosso-postural syndrome is characterized by a tendency to: increased physiological curves, abdominal protrusion with a deficit of the transverse muscle of the abdomen, anteversion of the

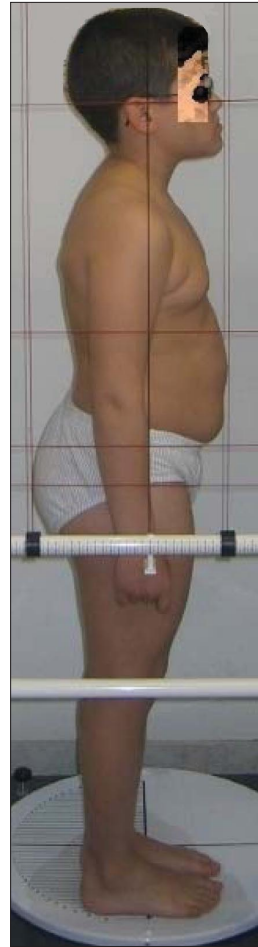


Figure 5 - Type 1 glosso-postural syndrome in subject with class III occlusion.

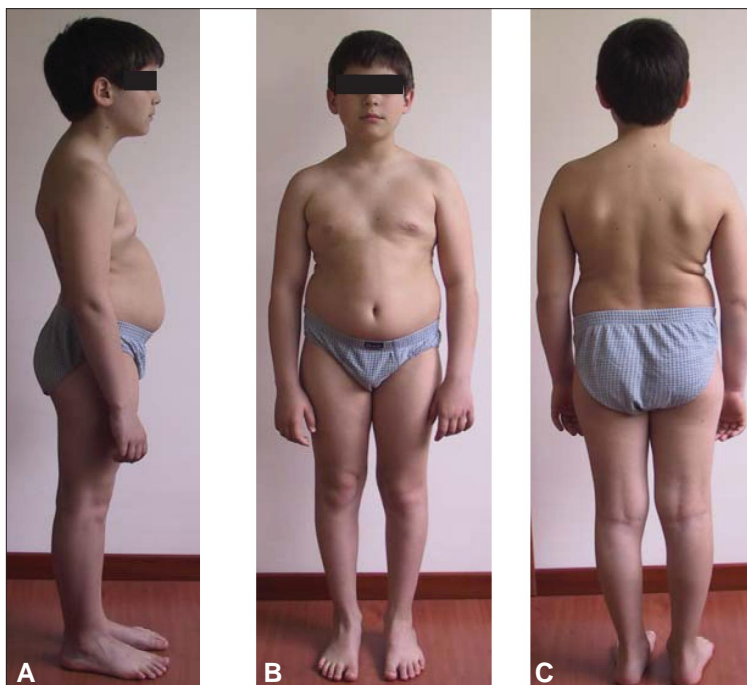


Figure 4 a, b, c - Type 1 glosso-postural syndrome.

pelvis, pronation of the foot, and valgism of the rear foot (Fig. 6).

Asymmetries of the torso may be present, as shown in figures 4c and 6a.

This forwards projection of the centre of gravity has important effects on posture, resulting in tension at cervicodorsal and lumbosacral joint, trochanter, femur-patella, sural triceps and forefoot level.

In addition to atypical deglutition, which is one of the most frequent causes, anterior pathological scars (Scoppa, 2004 a, b), and class II occlusions can also be responsible for anterior projection of the scapular plane.

To study this postural imbalance it is helpful to refer to an anterior body line, located in the sagittal plane, that links the symphysis menti to the pubic symphysis.

In type 1 glosso-postural syndrome, this anterior line falls forwards with respect to the pubic symphysis: indeed, the symphysis menti is shifted forwards, while the pubic symphysis is shifted backwards and downwards.

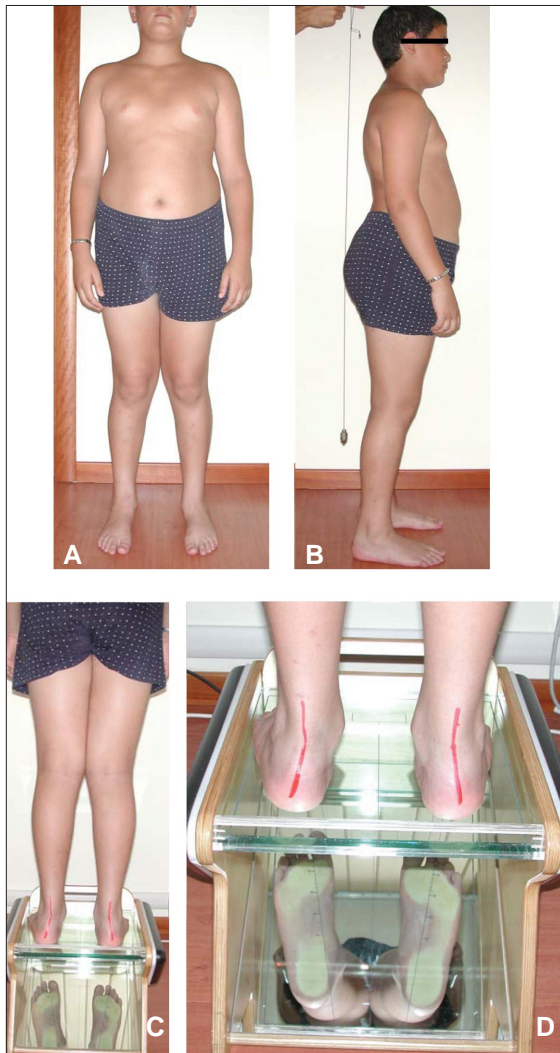


Figure 6 a, b, c, d - Type I glosso-postural syndrome. Please note: a – asymmetry of the torso, valgism of the lower limb; b – anterior scapula, evident abdominal protrusion, anteversion of the pelvis; c, d – rearfoot valgism and tendency to pronation.

In this condition, pressure is exerted on the abdominal muscle wall and on the anterior ligaments of the pelvis (especially Poupard's ligament), rather than on the bone structure of the pelvis, which is anteverted.

Furthermore, the increased dorsal kyphosis implies an increase in endoabdominal pressure, with the abdominal muscles tending to yield in order to reduce this pressure.

These considerations help us to understand why these patients typically show a protruding and weak abdominal wall (Figs 4a, 5, 6b), with a predisposition to abdominal ptosis and inguinal hernia.

In these conditions the synergistic-antagonistic relationship between the diaphragm and the abdominal transverse is altered: upper thoracic hypomobility and a modification of the diaphragmatic kinetics can easily develop, predisposing the subject to respiratory dysfunction.

In this postural picture, "upper crossed syndrome" and "lower crossed syndrome" are frequently present (Chaitow, 2001; Janda, 1983, 1991, 1993; Lewit, 1991) and, in time, can result in movement impairment syndromes (Sahrmann, 2002).

These crossed syndromes are due to a neuromuscular imbalance: the reciprocal relationship between synergistic and antagonistic muscles is permanently altered at the level of the cervicoscapulothoracic district and the lumbopelvic district.

There are two possible neurophysiological explanations for these imbalances:

- according to Sherrington's law of reciprocal innervation, a hyperactive and tight muscle inhibits its antagonist;
- at central control level, through alteration of motor and postural patterns, for every hyperprogrammed muscular chain with massive and early timing of activation, there is a hypoprogrammed antagonist chain with poor and delayed timing of activation. Generally, muscles with a prevalently tonic-postural function, predisposed to tension, shortening, and contractions, are in the first category, and prevalently phasic muscles, which are prone to weakness and hypotonia, are in the second.

Upper crossed neuromuscular imbalance

This type of imbalance is characterized by (Fig. 7):

- 1) weak lower fixator muscles of the scapular cingulum (serratus magnus and lower trapezius); strong upper fixators (scalenus muscles, scapular elevator, upper trapezius);
- 2) weak interscapular musculature and strong pectoral musculature;
- 3) weak deep flexor muscles of the neck (long flexor of the neck, long flexor of the head, omohyoid and thyrohyoid); strong neck extensors (paravertebral cervical, superior trapezius and scapular elevator).

On a neuromuscular level, if the lower fixators of the shoulder are weak, the upper fixators will become hyperactive and tight. Hyperactivity of the pectoral muscles brings about a forwards projection and rounding of the shoulders; weakness of the deep flexors of the neck produces an increase in upper cervical lordosis.

Furthermore, a shortening of the superior portion of the nuchal ligament may be present, which tends to lock

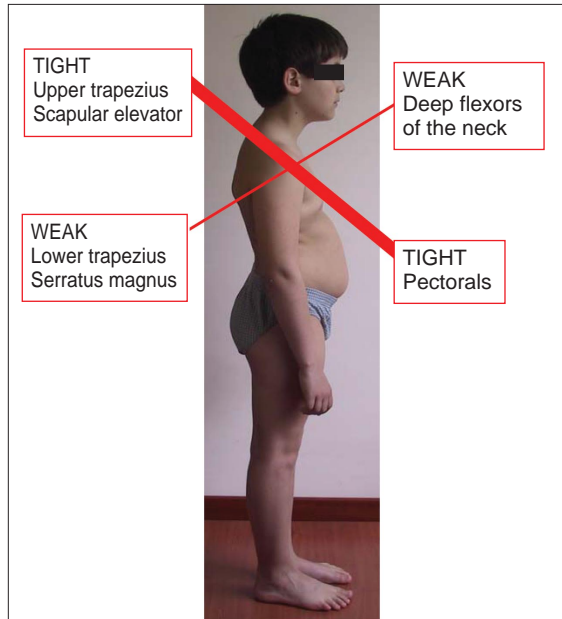


Figure 7 - Upper crossed neuromuscular imbalance.

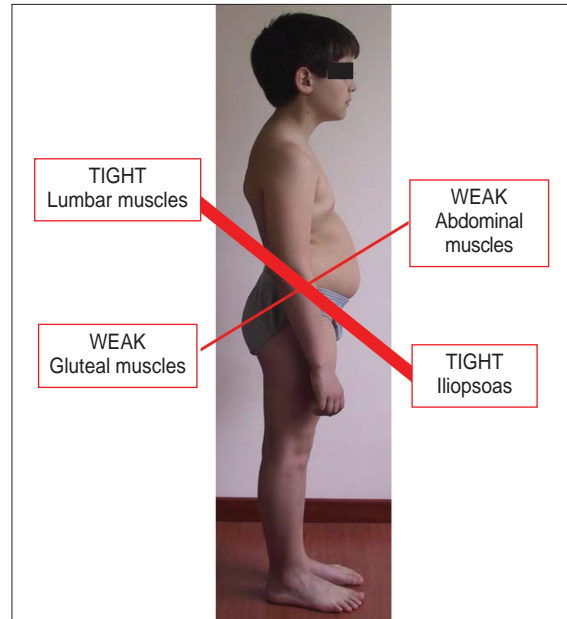


Figure 8 - Lower crossed neuromuscular imbalance.

the upper cervical rachis in lordosis: overall, the neck appears sunken and compressed (Fig.s 4a, 6b). In addition to producing dysfunctional motor and postural schemes, this upper crossed imbalance may influence and alter respiratory function and costodiaphragmatic dynamics.

Lower crossed neuromuscular imbalance

Lower crossed imbalance involves the following pairs of muscles (Fig. 8):

- 1) gluteus minimus (weak), and flexor muscles of the hip (hyperactive and tight);
- 2) abdominal musculature (weak), and lumbar paravertebral musculature (hyperactive and tight);
- 3) gluteus medius (weak), and lumbar quadratus muscles and tensor of the fascia lata (hyperactive and tight).

This neuromuscular imbalance implies actual “substitution” of muscles in the motor patterns, both in static and dynamic functions.

In order to achieve extension of the hip, weakness of the gluteal muscles is compensated for by the hyperprogramming of the lumbar and ischiocrural musculature. To guarantee adequate lateral lumbopelvic stabilization, the weakness of the gluteus medius is counteracted by compensatory activity of the tensor of the fascia lata and the lumbar quadratus muscles.

During flexion of the torso, a strong and tight iliopsoas muscle compensates for the weakness of the abdominal wall.

In postural terms, the result of these neuromuscular imbalances is anteversion of the pelvis with an increase in lumbar lordosis; in this context, shortened and tight ischiocrural muscles may be considered the expression of a compensating mechanism that seeks to reduce or stem the tendency towards anteversion of the pelvis.

Type II glosso-postural syndrome

Much less frequent than type I, this type of postural imbalance is characterized by an anomalous relationship between skull and torso, which, if not treated, persists in adulthood (Fig. 9).

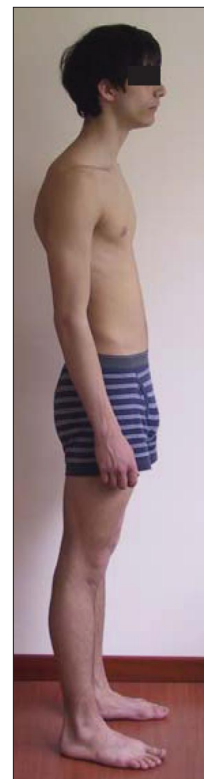

Figure 9 - Type II glosso-postural syndrome.

The scapular plane is posteriorized while the head is markedly anteriorized. This posture appears to be the crystallization of the protruding movement of the head that is typically performed during dysfunctional deglutition. The engram of this forward thrusting movement of the face ("chicken-like" movement during the act of swallowing) seems, in fact, to be fixed in the posture assumed by these individuals, which is particularly evident in the sagittal plane (Fig. 10).

The tongue is often low on the mandible and the occipito-atlantoid joint tends to be flexed.

On the contrary, in type I glosso-postural syndrome, the tongue is more frequently interposed anteriorly, with occipito-atlantoid extension.

In both cases, the anomalous behaviour of the tongue is normally associated with inadequate labial seal, and a tendency to oral respiration.

As in the type I syndrome, in this case too, the anomalous thrust of the tongue, low and anteriorized, tends to generate forces that, at postural level, develop prevalently in the sagittal plane. On the other hand, there is no tendency towards vertebral axial lengthening, thus the height of the body as a whole is reduced.

In both the syndrome types, the posture of the patient with glosso-postural syndrome shows absence of the righting reflex that occurs through the thrust of the tongue on the retroincisor spot.

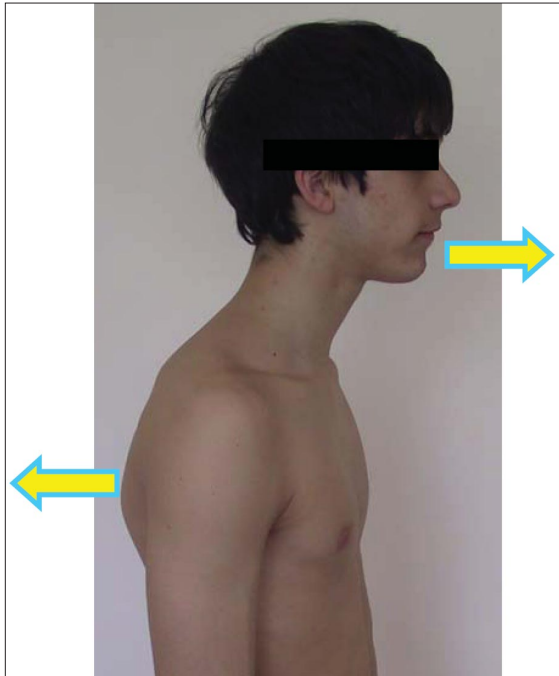


Figure 10 - In type II glosso-postural syndrome, the face is markedly anteriorized, while the scapular plane is posteriorized.

Conclusion

In conclusion, in considering the two nosographical entities here described, we must not allow ourselves to forget that the postural system is a non linear, dynamic

system (Scoppa, 2002, 2003, 2004 a); therefore, in the presence of other factors, in addition to atypical deglutition, that can perturb the tonic-postural equilibrium, other varieties of postural imbalance, including scoliotic types, cannot be ruled out.

Acknowledgements

I thank my collaborators, Dr M. Galifi Cerquetti and Dr R. Sipone for the support given in the preparation of this paper.

References

1. Balercia L, Balercia P. Fisiopatologia della deglutizione. Relazioni con occlusione e postura. *Dentista moderno* 1993; 1:55-83.
2. Bricot B. La reprogrammation posturale globale. Montpellier: Sauramps Medical, 1996.
3. Caprioglio D, Levrini A, Levrini L. Posizione di riposo della lingua e metodi di indagine. *Ortognatodonzia italiana* 1993a; 2:543-60.
4. Caprioglio D, Levrini A, Corsi C. Aumento della sensibilità della lingua nella deglutizione atipica. *Riv Ital Odontoiatrl Infant* 1993b; 2:21-8.
5. Capurso U, Marini I, Alessandri Bonetti G. I disordini cranio-mandibolari: fisioterapia speciale stomatognatica. Bologna: Edizioni Martina, 1996.
6. Chaitow L. Muscle energy techniques. London: Churchill Livingstone, 2001.
7. Cipollari E. La deglutizione. Aspetti posturali e strumenti diagnostici. Tesi Master in Posturologia, Relatore Prof. F. Scoppa, Università "La Sapienza" di Roma, a.a. 2002-2003.
8. Clauzade MA, Daraillans B. Concept osteopathique de l'occlusion. Perpignan: S.E.O.O. Editeur, 1989.
9. Clauzade MA, Daraillans B. L'homme, le crâne, les dents. Perpignan: S.E.O.O. Editeur, 1992.
10. Clauzade MA, Marty JP. Ortho posturodonthie. Perpignan: S.E.O.O. Editeur, 1998.
11. Cozza P, Di Girolamo R, Pisano L, Celano A, Nofroni I. Malocclusioni correlate alla deglutizione atipica. *Mondo Ortodontico* 1995; 6:521-8.
12. Cozza P, Polimeni A, De Toffol L. Manuale di Terapia miofunzionale. Milano: Masson, 2002.
13. Denys-Struyf G. Les chaines musculaires e articulaires. Paris: Maloine, 1982.
14. Ferrante A. Terapia miofunzionale: dalla deglutizione viziata ai problemi posturali, procedure diagnostiche e terapeutiche. Acquaviva Picena (AP): Futura Publishing Society, 1997.
15. Ferrante A. Manuale pratico di terapia miofunzionale. Roma: Marrapese Editore 2004.
16. Garliner D. Importanza di una corretta deglutizione. Acquaviva Picena (AP): Futura Publishing Society, 1996.
17. Funt LA, Stack B, Gelb S, Pivarnick MJ. Terapia miofunzionale nel trattamento della sindrome craniomandibolare. In: Gelb H. Trattamento clinico del dolore e della disfunzione dell'ATM, testa collo. Roma: Marrapese Editore, 1999, 609-63.
18. Guaglio G. Ortodonzia dinamica e ripristino delle funzioni. Perugia: Euroedizioni s.r.l., 2003.
19. Halata Z, Baumann KL. Sensory nerve endings in the hard palate and papilla incisiva of the rhesus monkey. *Anat Embryol (Berl)* 1999; 199:427-37.

20. Janda V. Muscle Function Testing. London: Butterworth, 1983.
21. Janda V. Muscle spasm - a proposed procedure for differential diagnosis. *Journal of Manual Medicine* 1991; 6:136-41.
22. Janda V. Muscle strength in relation to muscle length, pain and muscle imbalance, in: Harms-Rindahl K, ed *Muscle Strength*. New York: Churchill Livingstone, 1993.
23. Lentini S. *Ortodonzia e Postura*. Bologna: Edizioni Martina, 2003.
24. Lang IM, Dean C, Medda BK, Aslam M, Shaker R. Differential activation of medullary vagal nuclei during different phases of swallowing in the cat, *Brain Res* 2004; 1014: 145-63.
25. Lewit K. *Manipulative therapy in rehabilitation of the locomotor system*. Oxford: Butterworth, Heineman, 1991.
26. Lignon A. *Le puzzle crânien*. Aix en Provence: Editions de Verlaque, 1989.
27. Martin RE, Macintosh BJ, Smith RC, et al. Cerebral areas processing swallowing and tongue movement are overlapping but distinct: a functional magnetic resonance imaging (fMRI) study. *J Neurophysiol* 2004; 92:2428-43.
28. Peng CL, Jost-Brinkmann PG, Yoshida N, Chou HH, Lin CT. Comparison of tongue functions between mature and tongue-thrust swallowing – an ultrasound investigation. *Am J Orthod Dentofacial Orthop* 2004; 125:562-70.
29. Perronneaud-Ferré R. *Ostéopathie cranio-pelvienne. La technique des blocs*. Aix en Provence: Editions de Verlaque, 1989.
30. Ranaudo P, Seyr H. *Riflessioni sulla lingua*. Roma: Marrapese Editore, 1997.
31. Redstone F, West JF. The importance of postural control for feeding. *Pediatr Nurs* 2004; 30:97-100.
32. Sahrmann SA. *Diagnosis and treatment of movement impairment syndromes*. St. Louis: Mosby Inc., 2002.
33. Scoppa F. Posturologia: il modello neurofisiologico, il modello biomeccanico, il modello psicosomatico. *Otoneurologia* 2000 2002; 9:3 -13.
34. Scoppa F. Posturologia: dalla dinamica non lineare alla transdisciplinarietà. *Otoneurologia* 2000 2003; 15:28-47.
35. Scoppa F. Aggiornamenti scientifici in tema di Posturologia, 2004a; web site: www.chinesis.org
36. Scoppa F, Amabile G. Cicatrici patologiche e squilibri posturali/Pathological scars and postural disorders. *Résonances Européennes du Rachis* 2004b; 38:119-22.
37. Solomon NP, Munson B. The effect of jaw position on measures of tongue strength and endurance. *J Speech Lang Hear Res* 2004; 47: 584-94.
38. Spinicci M. Variazioni stabilometriche dopo normalizzazione linguale della deglutizione con metodo Garliner. Tesi Master in Posturologia, Relatore Prof. F. Scoppa, Università "La Sapienza" di Roma, a.a. 2002-2003.
39. Stefanelli G. *Sistema stomatognatico nel contesto posturale*. Milano: Edi Ermes, 2003.
40. Sutherland WG. *Texts fondateurs de l'ostéopathie dans le champ crânien*. Vannes, France: Editions Sully, 2002a.
41. Sutherland WG. *Enseignements dans la science de l'ostéopathie*. Fort Worth, Texas: Sutherland Cranial Teaching Foundation. Inc., 2002b.
42. Testut L, Latarjet A. *Anatomia Umana*. Torino: UTET, 1971.
43. Upledger JE, Vredevoogd JD. *Terapia craniosacrale. Teoria e metodo*. Como: Red Edizioni, 1996.
44. Walther DS, Garliner D. *Terapia miofunzionale*. In: Walther DS, ed *Kinesiologia applicata*, Vol. II. Milano: Castello Editore, 1996.
45. Zavarella P, Asmone C, Zanardi M. *Le asimmetrie occluso-posturali: relazione tra ortodonzia e postura*. Roma: Marrapese Editore, 2004.